

## Kartagener's Syndrome-A Rare Case Report

Dr. Aruna Bhattacharya<sup>1</sup>, Dr. Rama Saha<sup>2</sup>, Dr. Jaydip Deb<sup>3</sup>, Dr. Rituparna Basu<sup>4</sup>,  
Dr. Parthapratim Pradhan<sup>5</sup>

<sup>1</sup>Associate Professor, Department Of Biochemistry, B.S. Medical College & Hospital, Bankura, West Bengal, India

<sup>2</sup>Associate Professor, Department Of Pathology, IPGMER, Kolkata, West Bengal, India.

<sup>3</sup>Professor, Department of Pulmonary Medicine, N.R.S. Medical College & Hospital, Kolkata, West Bengal, India,

<sup>4</sup>Assistant Professor, Department of Anatomy, B. S. Medical College & Hospital, Bankura, West Bengal, India.

<sup>5</sup>Principal & Professor, Department Of Anatomy, B.S. Medical College & Hospital, Bankura, West Bengal, India.

---

**Abstract:** Kartagener syndrome is a subset of primary ciliary dyskinesia, an autosomal recessive condition characterized by abnormal ciliary structure or function leading to impaired mucociliary clearance. The findings of CT thorax, abdomen and PNS support the clinical diagnosis of the Kartagener's Syndrome. We report one of this rare syndrome from a rural Medical college & Hospital of West Bengal.

---

### I. Introduction

Kartagener's syndrome (KS) is a subgroup of primary ciliary dyskinesia (PCD). In KS, defective ciliary movement results in sinusitis, bronchiectasis, and dextrocardia due to ciliary dysmotility. So, heart along with the other organs fail to move on to the left side, resulting in dextrocardia and situs inversus. These patients usually present with repeated lower respiratory infection in childhood leading to bronchiectasis and infertility in adulthood we are hereby reporting a case of KS, who presented to us with cough and breathlessness.

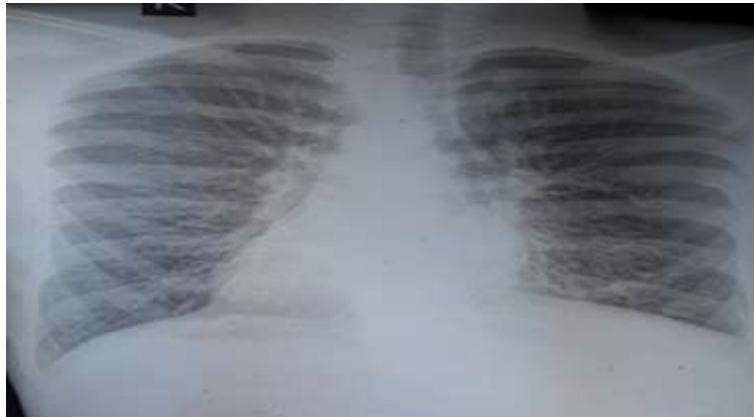### II. Case Report

An 18-year-old boy presented with 5 months dry cough with intermittent breathlessness. There was no fever or chest pain or hemoptysis. Cough and breathlessness were not associated with any postural or diurnal variation. He used to be affected with frequent cough and cold since childhood. No family history of asthma was present. Clinical examination revealed normal physical development with mild pallor and digital clubbing. His apex beat was palpable on the right 5<sup>th</sup> intercostal space in mid-clavicular line on palpation. Inspection and percussion findings were normal. Chest auscultation revealed bi-lateral rhonchi and basal coarse crepitations with clearly audible heart sounds on the right side.

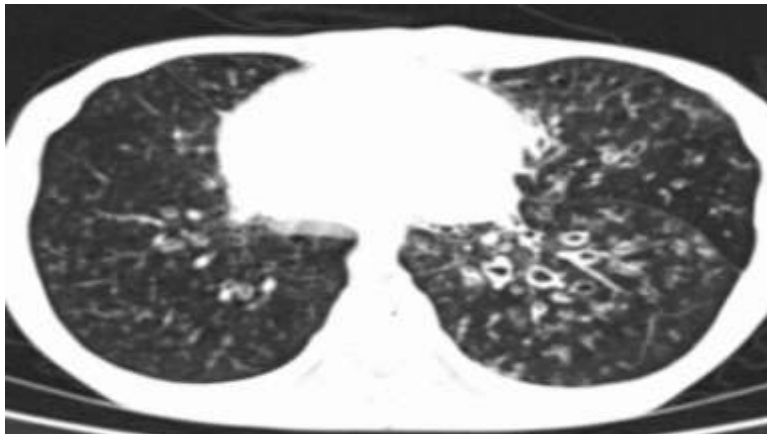
Cardio-vascular examination revealed right-sided 1<sup>st</sup> heart sound without any murmur. Other systemic examinations were normal. Chest X-ray revealed dextrocardia with normal lung field [Figure 1]. Sputum smear examination for acid fast bacillus was negative and aerobic culture showed growth of *Staphylococcus aureus*.

A high-resolution computerized tomography (HRCT) scan of thorax revealed bronchiectasis [Figure 2]. X-ray of paranasal sinuses revealed bi-lateral maxillary sinusitis [Figure 3]. HRCT abdomen (Figure 4) and Ultrasonography of the abdomen revealed situs inversus. Because of the presence of bronchiectasis, sinusitis, and dextrocardia, his semen analysis was done and it revealed complete aspermia with normal seminal fluid content.

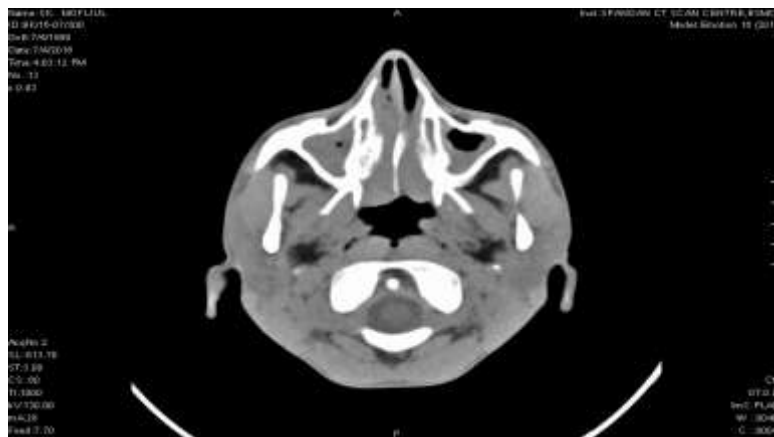
Fine needle aspiration cytology (FNAC) of the both testes revealed the presence of normal mature sperm, which indicated the inability of the sperm to be transported to the seminal fluid. The Saccharin test revealed delayed movement (35 minutes) of the particle toward oropharynx, which was indicative of impaired nasal ciliary movement. Echocardiography showed dextrocardia with without any structural abnormality. Routine blood count was within normal range. he pulmonary function test was of mixed pattern with significant bronchodilator reversibility.



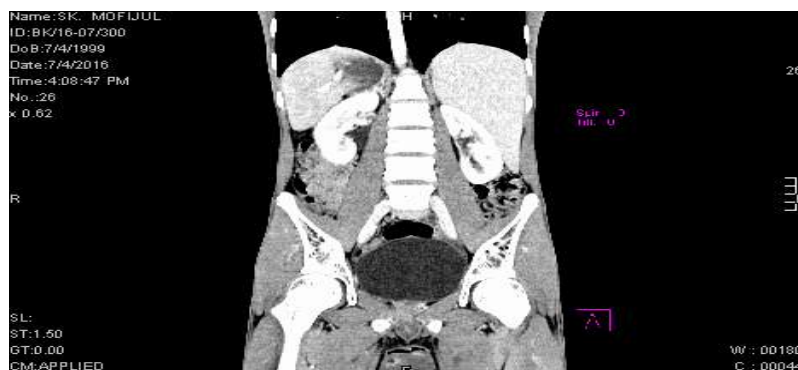**Figure 1** Chest X-ray showing dextrocardia with normal lung field



**Figure 2** HRCT thorax showing bronchiectasis



**Fig.3** X-ray of paranasal sinuses showing bilateral maxillary sinusitis



**Fig.4** CT abdomen showing situs invertus

He improved much after treatment with intravenous 1.2 g co-amoxycylav thrice daily, oral 600 mg linezolid twice daily along with nebulized salbutamol and budesonide for 28 weeks.

### III. Discussion

KS, also known as immotile cilia syndrome is a very rare disorder, found 1 in 26,000-40,000 live births. The prevalence of KS is around 1 in 60,000 populations,<sup>1</sup> more common among people with consanguineous marriages. Diagnostic triad of KS is bronchiectasis, chronic sinusitis, and situs inversus. All the defects develop due to defective ciliary movement. Among the many ciliary ultrastructural defects, the absence of one or both rows of dynein arms and the absence of spoke heads or central sheath are commonly seen in KS.<sup>2</sup> These dynein arms are ATPase radial projections, two of which normally arise from each of nine pairs of microtubules that run longitudinally and which are arranged circumferentially around the cilia. Ciliary bending occurs when outer microtubules slide over the inner microtubules in a coordinated fashion. Here, the energy is supplied by the dynein arms. This microtubular shortening initiates bending motion because the outer pairs of microtubules are tethered to each other and to the central sheath. Because of the same ultrastructural plane of symmetry, all cilia work in a coordinated fashion to propel the mucus blanket in a cephalic direction. Such coordinated sliding and bending cannot occur either in the absence of dynein arms or radial spokes.<sup>3</sup> A patient frequently suffers from repeated cough and cold since childhood leading to chronic sinusitis. Recurrent lower respiratory tract infection leads to bronchiectasis. A patient may have dextrocardia because of disorganized ciliary beating. Situs inversus, nasal polyps, rhinitis, corneal abnormalities, and conductive deafness are the other abnormalities found in KS.<sup>4</sup> However in our case, this adolescent boy came to us because of his recurrent chest infection and breathlessness, which was due to bronchiectasis.

Dextrocardia, hyperinflation of lungs, bronchial wall thickening, peribronchial infiltrates are found in chest X-ray though bronchiectasis and paranasal sinuses are better visualized by a CT scan.<sup>5</sup> Semen analysis of postpubertal males may reveal either abnormal sperm motility or aspermia. The Saccharin test is also used for diagnosis. A 0.5 mm saccharin particle is placed near inferior turbinate and its sweet test is felt in mouth within 30-60 minutes. Measuring exhaled nasal nitric oxide is a good screening test for immotile-cilia syndrome with a good negative predictive value.<sup>6</sup> Pulmonary function tests usually reveal an obstructive pattern in spirometry with a variable bronchodilator response. Static lung volumes may show hyperinflation. Gold-standard investigation is electron microscopic examination of cilia. Brush cytology from tracheal or bronchial mucus membrane provides the best specimen but cilia of the nasal epithelium are easy to collect. Sperm tail is the alternative good source of specimen. Video or electron microscopy of cilia for ciliary movement, beat frequency, co-ordination, and amplitude is commonly examined. In future, genetic testing will be the principal means of establishing the diagnosis.<sup>7</sup>

Haemophilus influenza, Staphylococcus aureus, and Pseudomonas species commonly colonize the bronchial tree of PCD patients. Antibiotics, intravenous or oral, intermittent or continuous, are used to treat upper and lower respiratory tract infections. In children, long-term low dose prophylactic antibiotics are sometimes necessary. Patients are also treated with inhaled bronchodilators inhaled corticosteroids, mucolytics, and chest physiotherapy. Influenza and pneumococcal vaccination should be routinely given.

### IV. Conclusion

Kartagener's syndrome should always be kept in mind in young patients with bronchiectasis and when Kartagener's syndrome is diagnosed, always look for the rare presence of aspermia. CT scan of the chest, particularly high-resolution CT (HRCT) scanning, has gained importance in severity, grading and monitoring of Kartagener's syndrome for clinical management and intervention studies. Consideration should be given to this imaging technique early in the presentation of Kartagener syndrome, when a chest radiograph may not be sensitive enough to identify disease processes or when another differential is being considered.<sup>8</sup>

### References

- [1]. Boat TF, Carson JL. Ciliary dysmorphology and dysfunction: Primary or acquired? *N Engl J Med.* 1990;323:1700-2.
- [2]. Afzelius BA. Immotile Cilia syndrome: Past, present and prospects for the future. *Thorax.* 1998;53:894-7.
- [3]. Sturgess JM, Chao J, Wong J, Aspin N, Turner JA. Cilia with defective radial spokes: A cause of human respiratory disease. *N Engl J Med.* 1979;300:53-6.
- [4]. Sturgess JM, Chao J, Turner JA. Transposition of ciliary microtubules: Another cause of impaired ciliary motility. *N Engl J Med.* 1980;303:318-22.
- [5]. Rutland J, de Jongh RU. Random ciliary orientation. A cause of respiratory tract disease. *N Engl J Med.* 1990;323:1681-4.
- [6]. Eliasson R, Mossberg B, Cammer P, Afzelius BA. The immotile cilia syndrome: A congenital ciliary abnormality as an etiologic factor in chronic airway infections and male sterility. *N Engl J Med.* 1977;297:1-6.
- [7]. Nadel HR, Stringer DA, Levison H, Turner JA, Sturgess JM. The immotile cilia syndrome: Radiological manifestations. *Radiology.* 1985;154:651-5.
- [8]. McManus I, Mitchison H, Chung E, Stubbings G, Martin N. Primary ciliary dyskinesia (Siewert's/Kartagener's syndrome): respiratory symptoms and psycho-social impact. *BMC Pulm Med* 2003; 3- 4.